

# A Multimodal Investigation of Neuronal/Axonal Integrity Using Structural T1-weighted Imaging, Diffusion Tensor Imaging, and <sup>1</sup>H MR Spectroscopy

Soyoung Choi<sup>1</sup>, Anand A Joshi<sup>2</sup>, Chitresh Bhushan<sup>2</sup>, Vincent Schmithorst<sup>3</sup>, Stefan Bluml<sup>4</sup>, David W Shattuck<sup>5</sup>, Richard M Leahy<sup>2</sup>, Hanna Damasio<sup>1</sup>, Ashok Panigrahy<sup>3</sup>, and Jessica L Wisnowski<sup>3,6</sup>

<sup>1</sup>Dana and David Dornsife Cognitive Neuroscience Imaging Institute, University of Southern California, Los Angeles, California, United States, <sup>2</sup>Signal and Image Processing Institute, University of Southern California, Los Angeles, California, United States, <sup>3</sup>Radiology, Children's Hospital of Pittsburgh of UPMC, Pittsburgh, PA, United States, <sup>4</sup>Department of Radiology, Children Hospital of Los Angeles, Los Angeles, CA, United States, <sup>5</sup>Laboratory of Neuro Imaging, UCLA School of Medicine, Los Angeles, CA, United States, <sup>6</sup>Brain and Creativity Institute, University of Southern California, Los Angeles, California, United States

## Target Audience

Researchers who are interested in integrating different sequences of MR imaging for a more detailed understanding of the cortex's macro and microstructure.

## Purpose:

Multimodal magnetic resonance (MR) imaging is increasingly becoming the standard in clinical practice and research yielding synergistic information regarding brain structure and brain function. Yet, very little is known about the extent to which metrics derived from diffusion tensor imaging (DTI), MR spectroscopy (MRS) and volumetric T1-weighted analyses can be directly related in different tissue types. For example, n-acetyl-aspartate (NAA), a product of mitochondrial metabolism in neurons and axons, is widely used as a biomarker of the density and integrity of neurons and axons at a specified spatial location. Similarly, fractional anisotropy (FA) and the apparent diffusion coefficient (ADC) have been used as biomarkers of tissue integrity in white matter (WM) and gray matter (GM), respectively. Finally, direct measurements of volume and cortical surface area have been associated with brain function as well as being indices of maturation in developing brains. We hypothesized that there will be a strong association among NAA, WM-FA, GM-ADC and volume measurements and that this relationship would be significant across tissue types.

## Methods:

The participant population consisted of a community sample of preadolescent twin pairs (ages 9-13 years) born late preterm (>32 weeks) and at full term recruited from a developing region in northeast Brazil (Montes Claros, pop. ca. 410,000) as part of an ongoing longitudinal international collaborative research program investigating the genetic and environmental influences relating prematurity, long-term neurocognitive functioning and health outcomes.

MRI scanning was performed on a Philips 1.5 T Achieva system. A 3D T1-weighted sequence (MPRAGE; 1mm isotropic acquisition) was acquired on 40 subjects (mean age = 11.45±1.43). The cerebrum was extracted in BrainSuite (David W. Shattuck, LONI, UCLA) using a semi-automated technique and segmented into 90 anatomical regions of interest using SVreg (Anand J. Joshi, USC) yielding outputs of volume (mm<sup>3</sup>), grey matter (GM) volume, white matter (WM) volume, and cortical surface area (CSA, mm<sup>2</sup>) for each ROI<sup>1</sup>. Furthermore, two additional regions of interest, corresponding to the voxel placement for the 1H-MRS acquisition (below) were delineated manually for each subject (designated as ACC and FMW; see below and Fig (d)).

Diffusion scans with 32 diffusion-encoding directions (Spin-Echo EPI, TR = 6 s, TE = 90 ms, b value = 1000 s/mm<sup>2</sup>, 2x2x2 mm<sup>3</sup>) were acquired on 38 participants (mean age = 11.40±1.45). DTI images were corrected for distortion<sup>2</sup> and coregistered to the T1 volumes and segmented as above using BrainSuite. DTI metrics (FA, ADC, axial diffusivity [AD], radial diffusivity [RD]) were then computed voxelwise after fitting a tensor model to the acquired diffusion-weighted images. The mean values were yielded separately for GM and WM within each of the 90 anatomical ROIs and in the ACC and FMW.

1H-MRS spectra were acquired from 10 cm<sup>3</sup> voxels places in the anterior cingulate cortex (ACC) and left frontal white matter (FWM) in 38 of the subjects above using a short-echo PRESS sequence: TR = 2000ms, TE = 35ms; 128 signal averages. Absolute concentrations of NAA and additional metabolites (not reported here) were quantitated from the MRS spectra using LCModel (Stephen Provencher Inc., Ontario, Canada; Ver. 6.1-4F). Data from two children were discarded due to poor signal to noise and associated motion artifacts.

Bivariate correlations were computed (SPSS, ver. 19, IBM corp.) between NAA concentration and GM-ADC in the ACC ROI as well as between those metrics and volume and cortical surface measurements obtained from the nearest anatomical region of interest (cingulate). Additional correlations were computed between the NAA concentration and WM-FA, -AD, and -RD metrics obtained in the ACC (i.e., obtained on the intragyrally white matter underneath the cortical GM in the ACC ROI). Finally, correlations were computed between NAA in the FWM and WM-FA, -AD, and -RD metrics obtained in that ROI, and between those metrics and volumetric and cortical surface area measurements obtained from these nearby anatomical regions of interest: cingulate, orbitofrontal, superior frontal, middle frontal and inferior frontal gyri. In this preliminary study, significance was set at  $p < 0.05$ , uncorrected.

## Results:

We found no association between ACC-NAA and GM-ADC in the ACC or between ACC-NAA and the volumetric and cortical surface area metrics obtained from the nearest anatomical region (cingulate). However, we did observe significant correlations between FWM-NAA and WM-FA in the FWM ( $r=0.467$ ,  $p<0.01$ ). In parallel with the FA results, analyses of AD and RD indicated a significant inverse correlation between NAA and RD FWM ( $r=-0.371$ ,  $p<0.05$ ), but no association with AD ( $p>0.4$ ).

Because the FWM voxel was in a region of crossing fibers containing fibers going to and from numerous frontal regions, we also tested whether there was any association between FWM-NAA and the DTI metrics in the FWM and volumetric and cortical surface area (CSA) measurements obtained from the nearest cortical regions. FWM-NAA was associated with total volume, GM volume and cortical surface area in the inferior frontal and orbitofrontal regions, as well as CSA in the middle frontal gyrus ( $r^2$ s: 0.3 – 0.39,  $p$ 's < 0.05). There were no associations among FWM-FA, -AD, or -RD and any of the volume and CSA metrics from the nearby cortical regions.

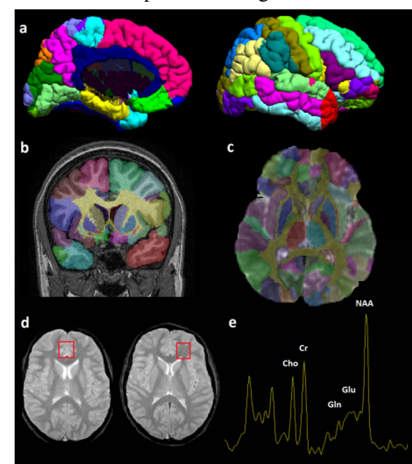
## Discussion:

Our results demonstrate an association between NAA and FA in the WM in preadolescents, replicating the results from a recent study in middle-aged and older adults<sup>3</sup>. Furthermore, we demonstrate that the association between NAA and FA is likely driven by an underlying association between NAA and RD, with little to no contribution of AD. In contrast, although ADC has been used at times as a biomarker for tissue microstructure in the GM, we found no association between NAA and ADC obtained from the same GM region. Finally we observed correlations between FWM-NAA and measurements of GM volume and CSA in nearby regions.

## Conclusion:

Using multimodal MR imaging methods we were able demonstrate an association between NAA concentration and FA, and more specifically, RD in the WM. The likely underlying biological basis for this association is that both metrics are reflecting the relative packing density of axons/fiber bundles at a given spatial location in the white matter.

**References:** [1] Joshi, WBIR 2012, LNCS Springer 180-189 [2] Bhushan,(APSIPA) Annual Summit and Conference, Hollywood, 2012, In Press. [3] Wijtenburg, NeuroImage (2012), doi: 10.1016/j.neuroimage.2012.10.014



**Figure.** Mesial and lateral views of cortical surfaces (a) and coronal slice (b) demonstrating anatomical segmentation of T1-volume using SVreg. After correcting for distortion artifacts in the DTI data, the T1- and DTI datasets were coregistered and the anatomical parcellation was transferred onto the DTI data (c). 1H-MRS spectra (e) were acquired from the ACC and frontal white matter as outlined (red box) in (d).